

INVESTIGATIVE REPORT

Effect of Dietary Supplementation with Omega-3 Fatty Acid and Gamma-linolenic Acid on Acne Vulgaris: A Randomised, Double-blind, Controlled Trial

Jae Yoon JUNG^{1,2,4}, Hyuck Hoon KWON^{1,2}, Jong Soo HONG¹, Ji Young YOON², Mi Sun PARK³, Mi Young JANG³ and Dae Hun SUH^{1,2}
¹Department of Dermatology, Seoul National University College of Medicine, ²Acne and Rosacea Research Laboratory, ³Department of Food Service and Nutrition Care, Seoul National University Hospital, and ⁴Oracle Dermatology Clinic, Seoul, Korea

This study was undertaken to evaluate the clinical efficacy, safety, and histological changes induced by dietary omega-3 fatty acid and γ -linoleic acid in acne vulgaris. A 10-week, randomised, controlled parallel dietary intervention study was performed in 45 participants with mild to moderate acne, which were allocated to either an omega-3 fatty acid group (2,000 mg of eicosapentaenoic acid and docosahexaenoic acid), a γ -linoleic acid group (borage oil containing 400 mg γ -linoleic acid), or a control group. After 10 weeks of omega-3 fatty acid or γ -linoleic acid supplementation, inflammatory and non-inflammatory acne lesions decreased significantly. Patient subjective assessment of improvement showed a similar result. Hematoxylin & eosin staining of acne lesions demonstrated reductions in inflammation and immunohistochemical staining intensity for interleukin-8. No severe adverse effect was reported. This study shows for the first time that omega-3 fatty acid and γ -linoleic acid could be used as adjuvant treatments for acne patients. *Key words: acne; γ -linoleic acid; omega-3 fatty acid.*

Accepted Jan 8, 2014; Epub ahead of print Feb 18, 2014

Acta Derm Venereol; 2014; 94: 521–525.

Dae Hun Suh, MD, PhD, Department of Dermatology, Seoul National University Hospital, 28 Yongon-dong, Chongno-gu, Seoul 110-744, Korea. E-mail: daehun@snu.ac.kr

Acne vulgaris is one of the most common skin diseases, but the pathogenic mechanism involved is not fully understood. Recently, the effect of diet intake on acne vulgaris has been widely discussed. For example, hyperglycaemic food-induced hyperinsulinaemia is proposed to lead endocrine responses that aggravate acne (1, 2), and a high glycemic load diet has been shown to affect acne in epidemiologic studies (1, 3, 4) and in randomised, controlled trials (5–7). Dairy foods could also aggravate acne vulgaris (8–11), and may influence comedogenesis because they contain androgens, 5 α -reduced steroids (e.g. dihydrotestosterone), and other non-steroidal growth factors that affect the pilosebaceous unit.

Many studies have investigated the influence of omega-3 fatty acid and γ -linolenic acid (GLA) on various diseases (12–31). Omega-3 fatty acid has anti-inflammatory and anti-cancer properties (20–22), but few well-controlled studies have been conducted on the influence of these fatty acids on acne. Typically, Western food contains a higher ratio of omega-6 to omega-3 fatty acids than non-Westernised food (1, 2). Omega-3 fatty acids inhibit the synthesis of the many pro-inflammatory molecules (12–23, 25, 32–34). GLA is one of the essential omega-6 fatty acids, but its dietary supplementation in patients with atopic dermatitis has produced inconsistent results. Nevertheless, it has anti-inflammatory effects on human skin epidermis, and it might play a physical structural role in skin barrier integrity (17, 24–28, 34–36). Therefore, we considered that the anti-inflammatory effects of omega-3 fatty acid and GLA might ameliorate acne vulgaris.

The aim of this study was to evaluate the clinical efficacy and safety of omega-3 fatty acids and of GLA for the treatment of mild to moderate facial acne. To our knowledge, this is the first randomised, double-blind, controlled study to be conducted on this topic.

MATERIAL AND METHODS

Study design and subjects

This study was designed as a 10-week, randomised, prospective, double-blind, controlled trial, and was conducted in accordance with the Declaration of Helsinki and approved by the Institutional Review Board of Seoul National University Hospital (Institutional Review Board approval No. H-1007-081-323). Informed consent was obtained from all study subjects. Subjects were not allowed to use any systemic, topical, or phototherapy-based acne treatment during the course of this study. The exclusion criteria applied were: pregnancy, lactation, seafood allergy, consumption of dietary supplements, systemic immunomodulatory or prior acne therapy, such as systemic antibiotic therapy (for any indication), the use of a topical acne preparation, or an intra-lesional steroid injection within one month or isotretinoin therapy within 6 months of study commencement.

Forty-five acne patients with mild to moderate acne were included in this study. The study subjects were allocated to matched groups of 3 and then randomised to treatment groups, the omega-3 group, the GLA group, or the control group. A random blocked allocation sequence was created by computer-

generated randomisation and allocation to specific groups was performed by a research nurse.

Dietary intervention and clinical outcome assessments

The omega-3 group took 2 capsules containing eicosapentaenoic acid (EPA) and docosahexaenoic acid (DHA) daily; each omega-3 fatty acid capsule contained 500 mg of EPA and 500 mg of DHA. The GLA group also took 2 capsules daily; each capsule contained 1,000 mg of borage oil containing 200 mg of GLA. All capsules used had the same colour (yellowish transparent), size, shape (oval), and smell (no smell). Four patient follow-ups were scheduled during the 10-week treatment period (weeks 0, 2, 5, and 10). Control group members were not given or took any type of treatment. Qualified nutritionists (MSP, MYJ) instructed participants to maintain a regular diet, caloric intake, and dietary nutritional composition. All 45 study subjects were provided with a food diary and instructions on how to complete the diary. Subjects were required to note the type of food and amount of food eaten daily. A qualified nutritionist analysed the food diary at all follow-up visits.

Standardised digital photographs were taken before treatment and at all follow-up visits using identical camera settings (D70, Nikon, Tokyo) and lighting conditions. Two independent dermatologists (DHS, JYJ) checked facial skin, performed inflammatory and non-inflammatory acne counts, and evaluated acne severity using the Cunliffe grading system (37). All subjects were asked to self-evaluate acne severity using a visual analogue scale (VAS) ranging from 0 (disease-free status) to 10 (acne status at initial visit). Thus, when acne was aggravated as compared with initial visits, VAS scores exceeded 10.

Histopathology and immunohistology

For histological analysis, 2-mm punch biopsy was performed on facial acne lesions before treatment and at final visits. Seven patients were selected from each group and one of the active acne lesions from the cheek was used for punch biopsy in each patient. Specimen sections were stained with haematoxylin-eosin (H&E) and immunohistological analyses were done using antibodies for interleukin-8 (IL-8) (Affinity Bioreagents, Golden, CO, USA), and transforming growth factor beta 1 (TGF- β 1) (Santa Cruz Biotechnology, Santa Cruz, CA, USA). The severity of inflammation on the H&E staining was ranked by using a 5-point scale, from 0 (no inflammation) to 4 (very severe inflammation). Staining intensities for IL-8 and TGF- β 1 were ranked using a 5-point scale from 0 (unstained) to 4 (very intensively stained). The skin biopsy and histopathological evaluations were performed by 2 independent dermatologists. Treatment groups and tissue examinations before and after treatment were also blinded.

Statistical analysis

The Mann-Whitney test was used to evaluate the significances of intergroup differences. Repeated statistical analyses using analysis of variance (ANOVA) were performed to evaluate the significances of longitudinal changes. SPSS software (version 12.0, SPSS Inc, Chicago, IL, USA) was used throughout, and *p*-values of <0.05 were considered statistically significant.

RESULTS

Initially 62 subjects were screened, but 17 subjects failed to meet the inclusion criteria. In total 45 subjects (36 men, 9 women) were enrolled, and everyone

completed the study. Mean subject age was 23.7 years (range, 18–33 years). Forty-five subjects were randomly assigned to the 3 groups (Fig. S1¹). Total dietary energy intake, glycaemic load, glycaemic index, and nutritional composition were similar in the 3 groups at any time during the study.

Acne counts (Fig. 1 A and B)

At final visits (after 10 weeks of intervention), the mean inflammatory acne lesion count was significantly reduced in the omega-3 group from 10.1 ± 3.2 to 5.8 ± 3.4 ($p < 0.05$). A similar change was observed in the GLA group (9.8 ± 5.2 before vs. 8.0 ± 4.6 after 5 weeks vs. 6.6 ± 3.7 after 10 weeks, $p < 0.05$). However, no significant change was observed in the control group (9.9 ± 4.3 before to 10.2 ± 6.2 after 10 weeks).

Mean non-inflammatory acne lesion counts were also reduced by omega-3 and GLA supplementation (23.5 ± 9.2 to 18.9 ± 8.3 , $p < 0.05$, and 22.8 ± 8.4 to 19.2 ± 7.2 , $p < 0.05$, respectively) at final visits, whereas mean lesion count in the control group was unchanged (from 21.8 ± 9.7 to 22.0 ± 8.6).

Significant differences were evident between the treatment groups and the control group after 10 weeks ($p < 0.05$). However, no significant difference was found between the 2 treatment groups in terms of mean inflammatory or non-inflammatory acne lesion count.

Clinical photographs showing typical improvements after omega-3 fatty acid and GLA supplementation are shown in Fig. S2¹.

Acne severity (Fig. 1C)

Mean baseline acne grades in the omega-3 and GLA groups were 2.4 and 2.3, respectively. After 5 weeks of treatment, grades were decreased to 1.9 and 2.0, respectively, and at final visits, they reduced to 1.7 ($p < 0.05$) and 1.8 ($p < 0.05$), respectively. No significant change in acne severity was observed in the control group at any time. At final visits, significant differences were observed between the treatment groups and the control group ($p < 0.05$).

Patient subjective assessments (Fig. 2)

Acne status at initial visits were set arbitrarily at 10 on a VAS scale. After 5 weeks of treatment, VAS scores started to decrease in the 2 treatment groups (to 7.6 in the omega-3 group ($p < 0.05$) and to 8.0 in the GLA group ($p < 0.05$)), and at final visits, VAS scores were further reduced to 6.5 ($p < 0.05$) and 6.8 ($p < 0.05$), respectively. No significant difference was found between these 2 groups by subjective assessment at any

¹<http://www.medicaljournals.se/acta/content/?doi=10.2340/00015555-1802>

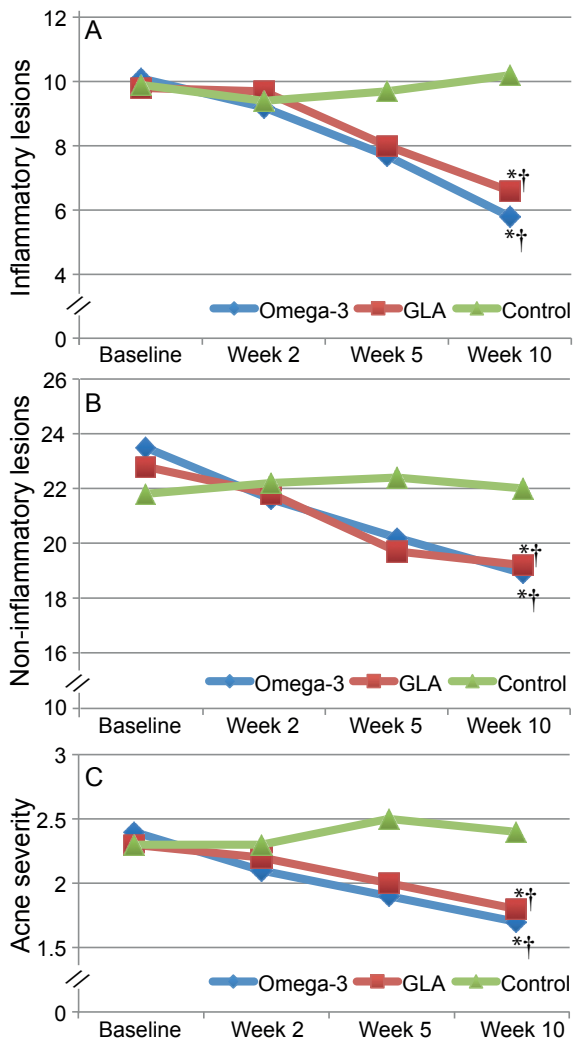


Fig. 1. Changes in inflammatory acne lesion counts with time (A), non-inflammatory acne lesion counts with time (B) and acne severity with time (C). * $p < 0.05$ versus baseline; † $p < 0.05$, versus control.

follow-up visit, but the VAS scores of both treatment groups differed significantly from the control group already at 5 weeks of supplementation.

Histopathology and immunohistology (Fig. S3¹)

H&E staining of acne lesions demonstrated reductions in inflammation in the omega-3 group during the 10-week treatment period (2.1 pre-treatment to 1.6 post-treatment, $p < 0.05$) and in the GLA group (2.0 to 1.6, $p < 0.05$). Immunohistochemical staining intensities for IL-8 were significantly decreased in the treatment groups (1.9 to 1.5 in the omega-3 group, $p < 0.05$, and 1.8 to 1.4 in the GLA group, $p < 0.05$), and intensities for TGF- β 1 were slightly but not significantly increased (1.1 to 1.2 in the omega-3 group, and 1.0 to 1.2 in the GLA group). However, no significant difference was found between the 2 treatment groups. No significant change in the intensities of H&E staining or immunohistochemical staining was observed in the control group.

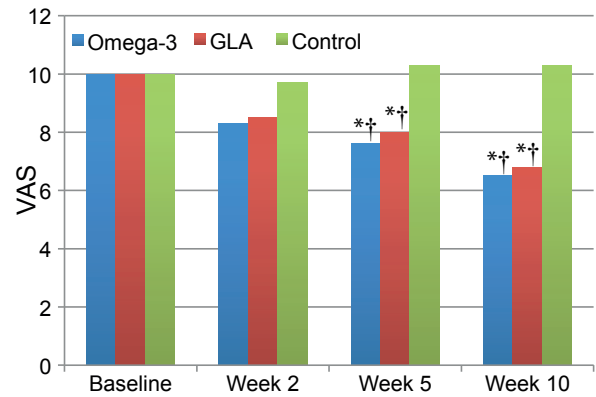


Fig. 2. Changes in patients' subjective assessment (VAS) with time; * $p < 0.05$ versus baseline; † $p < 0.05$ versus control.

Side effects and safety

Two patients in the omega-3 group (13.3%) and one in the GLA group (6.7%) reported mild gastrointestinal discomfort, and one patient in the omega-3 group (6.7%) reported temporary diarrhoea. However, these complications resolved spontaneously within a few days without treatment. No severe adverse effects were noted.

DISCUSSION

Omega-3 fatty acid has been used to treat various diseases, for example atopic dermatitis, psoriasis, blepharitis, meibomian gland dysfunction, autoimmune disease, cardiovascular disease, and prostate and colon cancer (12–25, 33, 34). However, only few studies have been undertaken to examine the effect of omega-3 fatty acid supplementation on acne. One epidemiological study found that adolescents who consumed large amounts of fish and seafood, which are both rich in omega-3 fatty acids, appeared to be less prone to manifest acneiform lesions, and concluded that omega-3 fatty acids might have beneficial effects on acne (38). In another acne case study of an omega-3-based dietary supplement (containing 1,000 mg EPA from fish oil, epigallocatechin-3-gallate, zinc gluconate, selenium, and chromium), it was suggested that supplementation possibly ameliorated inflammatory papules and improved global aspects of well-being (12). However, this study was an observational trial without a control group conducted on a small number of patients. In the present study, the omega-3 supplementation group ($n = 15$) received 2,000 mg of EPA and DHA daily for 10 weeks in capsules, which contained no other components. A Korean pharmacy company (Chong Kun Dang, Seoul) prepared the omega-3 fatty acid capsules from fish oil and the GLA capsules from borage oil, in such a way that the capsules were indistinguishable. However, this study has limitations in that the control group did not receive any capsules and hence there was no placebo group. All participants were instructed to record food intake daily starting one week

before study commencement to the end of the study. In addition, qualified nutritionists reviewed food diaries, calculated calories, nutritional contents, and instructed subjects to maintain a regular dietary pattern.

Omega-3 fatty acids can ameliorate inflammation in different ways. First, omega-3 fatty acids compete with arachidonic acid (AA) for incorporation into cell membrane phospholipids and serve as substrate for cyclooxygenase-2 (COX-2) and 5-lipoxygenase (5-LOX) (12–25, 33, 34, 39–41). This leads to reduction in the production of prostaglandin E2 (PGE2) metabolites, thromboxane A2 (a potent platelet aggregator and vasoconstrictor), and leukotriene B4 (a potent inducer of inflammation, leucocyte chemotaxis, and adherence), and increase in the production of thromboxane A3 (a weak platelet aggregator and vasoconstrictor), prostacyclin PGI3 (an active vasodilator), leukotriene B5 (a weak inducer of inflammation and a weak chemotactic agent) (12–25, 33, 34, 39). Secondly, omega-3 fatty acids are believed to affect several aspects of monocyte cell function, and they inhibit T-cell activation and proliferation *in vivo* and reduces circulating granulocyte levels (18). Thirdly, omega-3 fatty acid supplementation inhibits IL-1, IL-6, IL-8, and TNF- α secretion, which are the principal mediators of acne inflammation (23, 39, 42). EPA has been shown to suppress the NF- κ B activation induced by various stimuli, and to inhibit TNF- α -induced MMP-9 expression by inhibiting the activation of p38 and Akt (32). Finally, omega-3 fatty acids may help to reduce inflammatory responses by altering the levels of TLR-2 and TLR-4 (43). During the development of acne, *P. acnes* induces the activation of TLR-4 and TLR-2, which leads to the maintenance of inflammation by keratinocytes (43–45). Thus, because inflammation is one of the most important pathogenic factors of acne vulgaris, omega-3 fatty acid could ameliorate acne vulgaris (46, 47). In the present study, inflammatory cell levels, determined histopathologically, were significantly reduced after 10 weeks of omega-3 fatty acid supplementation.

In addition to its anti-inflammatory effects, omega-3 fatty acid has also been shown to decrease the serum level insulin-like growth factor-1 (IGF-1) and increase insulin-like growth factor binding protein-3 (IGFBP-3) (33, 48, 49). IGF-1 stimulates basal keratinocyte proliferation, sebum production, and the synthesis of androgens in ovaries and testes, and hence, increases the sebum production inducing effects on circulating androgens (1, 2, 4, 7). Furthermore, IGFBP-3 prevents IGF-1 from binding to its receptor, and is a pro-apoptotic factor in epithelial cells (1, 2, 4, 7). Therefore, omega-3 fatty acid supplementation could also reduce the severities of non-inflammatory acne lesions, as was observed in the present study.

GLA is an omega-6 fatty acid obtained from borage oil, and has been used by dermatologists to treat atopic dermatitis and psoriasis (26–28). However, no report has

been issued on the effect of GLA on acne. The present study suggests that GLA could improve acne vulgaris in 2 ways. First, GLA modulates the inflammatory process. Briefly, it is converted into dihomo- γ -linolenic acid (DGLA), a substrate for cyclo-oxygenase and 15-lipoxygenase (Fig. S4¹), which catalyses the production of prostaglandin E1 (PGE1) and 15-hydroxydihomo- γ -linolenic acid (15-OH-DGLA), respectively (26, 35, 36). PGE1 and 15-OH-DGLA have anti-inflammatory properties. PGE1 inhibits proinflammatory cytokines, such as TNF, IL-1 β , and IL-6 (the principal mediators of acne inflammation), and 15-OH-DGLA inhibits 5-lipoxygenase, and thus reduces the production of the AA-derived pro-inflammatory eicosanoids, such as leukotrienes B4 and C4. In fact, the anti-acne effects of the inhibition of leukotriene B4 formation have already been demonstrated not only by experimental results but also by systemic administration of the 5-lipoxygenase inhibitor zileuton for acne patients (50–53). DGLA can also be converted into AA by Δ 5-desaturase, and AA finally produces the pro-inflammatory mediators PGE2 and leukotrienes (26, 35, 36). However, because Δ 5-desaturase is not present in the epidermis, GLA supplementation will not increase AA or prostaglandin E2 levels in skin (26). Thus, GLA supplementation could increase only PGE1 and 15-OH-DGLA concentrations, and improve inflammatory acne lesions and underlying inflammation around uninvolved follicles.

Secondly, the GLA metabolite 15-OH-DGLA can improve hyperproliferative skin conditions. 15-OH-DGLA has been reported to modulate nuclear protein kinase C (PKC)/mitogen-activated protein-kinase (MAPK) (36). Alterations in the keratinocyte of PKC/MAPK could affect the regulation of downstream nuclear events, such as those involving activator protein-1 (AP-1). Thus, 15-OH-DGLA could alleviate hyperproliferative skin disorders via the modulation of transcription factor AP-1 and apoptosis (36). In the present study, the anti-proliferative effect of 15-OH-DGLA may have corrected follicular hyperkeratinisation that is a primary feature of acne vulgaris, and thus, improved non-inflammatory acne lesions.

In previous studies, omega-3 fatty acids were administered at 1.0–5.4 g/day for 2 to 12 weeks (13, 15, 16, 25, 29–31), and GLA was administered at 100–480 mg for 8–12 weeks (26–28). In the present study, subjects received either 2,000 mg of omega-3 fatty acid daily or 400 mg of GLA daily for 10 weeks, which are similar doses to those used in previous studies. In order to increase compliance, we have chosen to administer the agents orally, and we increased capsule content to 1,000 mg to minimise the number required per day. No difficulties were reported regarding taking the capsules. Furthermore, no serious side effects were encountered after administering 2,000 mg of omega-3 fatty acid and GLA for 10 weeks, and there were no study dropouts.

In the present study, histopathological changes in acne lesions corresponded well with clinical results. H&E staining of acne lesions showed significant reductions in inflammation in the omega-3 and GLA groups. However, sebaceous gland volumes were similar to baseline in both treatment groups. On the other hand, immunostaining intensities of IL-8, which is associated with epidermal hyperplasia, follicular hyperkeratosis, and acne inflammation, were significantly reduced (40, 54–56). TGF- β mainly participates in early wound healing and neocollagenesis, therefore a 10-week treatment period may have been too long to observe changes (57–59).

No significant differences were observed between the omega-3 and GLA groups in terms of acne improvement, although the omega-3 group showed slightly better results. Furthermore, the action onset and acne severity pattern of the 2 treatment groups were similar.

This controlled study provide first evidence that moderate doses of omega-3 fatty acid (DHA, EPA) or GLA can improve acne lesions. Histopathological findings corresponded well with the clinical response. Furthermore, omega-3 fatty acid and GLA supplementation at the moderate doses used were found to be both tolerable and safe, and offer a suitable adjuvant treatment scheme for mild to moderate acne vulgaris.

ACKNOWLEDGEMENT

This study was supported by a grant of the Korea HealthcareTechnology R&D Project, Ministry for Health, Welfare & Family Affairs, Republic of Korea (A090411) and a grant No. 03-2007-0290 from the Seoul National University Hospital Research Fund.

The authors declare no conflict of interest.

REFERENCES

1. Cordain L, Lindeberg S, Hurtado M, Hill K, Eaton SB, Brand-Miller J. Acne vulgaris: a disease of western civilization. *Arch Dermatol* 2002; 138: 1584–1590.
2. Cordain L. Implications for the role of diet in acne. *Semin Cutan Med Surg* 2005; 24: 84–91.
3. Steiner PE. Necropsies on Okinawans; anatomic and pathologic observations. *Arch Pathol* 1946; 42: 359–380.
4. Jung JY, Yoon MY, Min SU, Hong JS, Choi YS, Suh DH. The influence of dietary patterns on acne vulgaris in Koreans. *Eur J Dermatol* 2010; 20: 768–772.
5. Smith RN, Braue A, Varigos GA, Mann NJ. The effect of a low glycemic load diet on acne vulgaris and the fatty acid composition of skin surface triglycerides. *J Dermatol Sci* 2008; 50: 41–52.
6. Smith RN, Mann NJ, Braue A, Makelainen H, Varigos GA. The effect of a high-protein, low glycemic-load diet versus a conventional, high glycemic-load diet on biochemical parameters associated with acne vulgaris: a randomized, investigator-masked, controlled trial. *J Am Acad Dermatol* 2007; 57: 247–256.
7. Kwon HH, Yoon JY, Hong JS, Jung JY, Park MS, Suh DH. Clinical and histological effect of a low glycaemic load diet in treatment of acne vulgaris in Korean patients: a

- randomized, controlled trial. *Acta Derm Venereol* 2012; 92: 241–246.
8. Danby FW. Acne and milk, the diet myth, and beyond. *J Am Acad Dermatol* 2005; 52: 360–362.
9. Adebamowo CA, Spiegelman D, Berkey CS, Danby FW, Rockett HH, Colditz GA, et al. Milk consumption and acne in adolescent girls. *Dermatol Online J* 2006; 12: 1.
10. Adebamowo CA, Spiegelman D, Berkey CS, Danby FW, Rockett HH, Colditz GA, et al. Milk consumption and acne in teenaged boys. *J Am Acad Dermatol* 2008; 58: 787–793.
11. Adebamowo CA, Spiegelman D, Danby FW, Frazier AL, Willett WC, Holmes MD. High school dietary dairy intake and teenage acne. *J Am Acad Dermatol* 2005; 52: 207–214.
12. Rubin MG, Kim K, Logan AC. Acne vulgaris, mental health and omega-3 fatty acids: a report of cases. *Lipids Health Dis* 2008; 7: 36.
13. Koch C, Dolle S, Metzger M, Rasche C, Jungclas H, Ruhl R, et al. Docosahexaenoic acid (DHA) supplementation in atopic eczema: a randomized, double-blind, controlled trial. *Br J Dermatol* 2008; 158: 786–792.
14. Bjerneboe A, Smith AK, Bjerneboe GE, Thune PO, Drevon CA. Effect of dietary supplementation with n-3 fatty acids on clinical manifestations of psoriasis. *Br J Dermatol* 1988; 118: 77–83.
15. Soyland E, Funk J, Rajka G, Sandberg M, Thune P, Rustad L, et al. Effect of dietary supplementation with very-long-chain n-3 fatty acids in patients with psoriasis. *N Engl J Med* 1993; 328: 1812–1816.
16. Mayser P, Grimm H, Grimminger F. n-3 fatty acids in psoriasis. *Br J Nutr* 2002; 87 Suppl 1: S77–82.
17. Kragballe K. Dietary supplementation with a combination of n-3 and n-6 fatty acids (super gamma-oil marine) improves psoriasis. *Acta Derm Venereol* 1989; 69: 265–268.
18. Din JN, Newby DE, Flapan AD. Omega 3 fatty acids and cardiovascular disease – fishing for a natural treatment. *BMJ* 2004; 328: 30–35.
19. Laganieri S, Yu BP, Fernandes G. Studies on membrane lipid peroxidation in omega-3 fatty acid-fed autoimmune mice: effect of vitamin E supplementation. *Adv Exp Med Biol* 1990; 262: 95–102.
20. Menendez JA, Lupu R, Colomer R. Exogenous supplementation with omega-3 polyunsaturated fatty acid docosahexaenoic acid (DHA; 22: 6n-3) synergistically enhances taxane cytotoxicity and downregulates Her-2/neu (c-erbB-2) oncogene expression in human breast cancer cells. *Eur J Cancer Prev* 2005; 14: 263–270.
21. Manda K, Kriesen S, Hildebrandt G, Fietkau R, Klautke G. Omega-3 fatty acid supplementation in cancer therapy: does eicosapentaenoic acid influence the radiosensitivity of tumor cells? *Strahlenther Onkol* 2011; 187: 127–134.
22. Andreeva VA, Touvier M, Kesse-Guyot E, Julia C, Galan P, Hercberg S. B vitamin and/or omega-3 fatty acid supplementation and cancer: ancillary findings from the supplementation with folate, vitamins B6 and B12, and/or omega-3 fatty acids (SU.FOL.OM3) randomized trial. *Arch Intern Med* 2012; 172: 540–547.
23. Macsai MS. The role of omega-3 dietary supplementation in blepharitis and meibomian gland dysfunction (an AOS thesis). *Trans Am Ophthalmol Soc* 2008; 106: 336–356.
24. Thies F, Nebe-von-Caron G, Powell JR, Yaqoob P, News-holme EA, Calder PC. Dietary supplementation with gamma-linolenic acid or fish oil decreases T lymphocyte proliferation in healthy older humans. *J Nutr* 2001; 131: 1918–1927.
25. Mayser P, Mayer K, Mahloudjian M, Benzing S, Kramer HJ, Schill WB, et al. A double-blind, randomized, placebo-controlled trial of n-3 versus n-6 fatty acid-based lipid

- infusion in atopic dermatitis. *J Parenter Enteral Nutr* 2002; 26: 151–158.
26. Van Gool CJ, Thijs C, Henquet CJ, van Houwelingen AC, Dagnelie PC, Schrandt J, et al. Gamma-linolenic acid supplementation for prophylaxis of atopic dermatitis – a randomized controlled trial in infants at high familial risk. *Am J Clin Nutr* 2003; 77: 943–951.
 27. Foster RH, Hardy G, Alany RG. Borage oil in the treatment of atopic dermatitis. *Nutrition* 2010; 26: 708–718.
 28. Andreassi M, Forleo P, Di Lorio A, Masci S, Abate G, Amerio P. Efficacy of gamma-linolenic acid in the treatment of patients with atopic dermatitis. *J Int Med Res* 1997; 25: 266–274.
 29. Balbas GM, Regana MS, Millet PU. Study on the use of omega-3 fatty acids as a therapeutic supplement in treatment of psoriasis. *Clin Cosmet Investig Dermatol* 2011; 4: 73–77.
 30. Rhodes LE, O'Farrell S, Jackson MJ, Friedmann PS. Dietary fish-oil supplementation in humans reduces UVB-erythema sensitivity but increases epidermal lipid peroxidation. *J Invest Dermatol* 1994; 103: 151–154.
 31. Frati C, Bevilacqua L, Apostolico V. Association of etretinate and fish oil in psoriasis therapy. Inhibition of hypertriglyceridemia resulting from retinoid therapy after fish oil supplementation. *Acta Derm Venereol* 1994; 186: 151–153.
 32. Kim HH, Lee Y, Eun HC, Chung JH. Eicosapentaenoic acid inhibits TNF-alpha-induced matrix metalloproteinase-9 expression in human keratinocytes, HaCaT cells. *Biochem Biophys Res Commun* 2008; 368: 343–349.
 33. Logan AC. Omega-3 fatty acids and acne. *Arch Dermatol* 2003; 139: 941–942; author reply 942–943.
 34. Eriksen BB, Kare DL. Open trial of supplements of omega 3 and 6 fatty acids, vitamins and minerals in atopic dermatitis. *J Dermatol Treat* 2006; 17: 82–85.
 35. Pinna A, Piccinini P, Carta F. Effect of oral linoleic and gamma-linolenic acid on meibomian gland dysfunction. *Cornea* 2007; 26: 260–264.
 36. Ziboh VA, Cho Y, Mani I, Xi S. Biological significance of essential fatty acids/prostanoids/lipoxygenase-derived monohydroxy fatty acids in the skin. *Arch Pharm Res* 2002; 25: 747–758.
 37. O'Brien SC, Lewis JB, Cunliffe WJ. The Leeds revised acne grading system. *J Dermatol Treat* 1998; 9: 215–220.
 38. Hitch JM, Greenburg BG. Adolescent acne and dietary iodine. *Arch Dermatol* 1961; 84: 898–911.
 39. Simopoulos AP. Omega-3 fatty acids in inflammation and autoimmune diseases. *J Am Coll Nutr* 2002; 21: 495–505.
 40. Alestas T, Ganceviciene R, Fimmel S, Müller-Decker K, Zouboulis C. Enzymes involved in the biosynthesis of leukotriene B4 and prostaglandin E2 are active in sebaceous glands. *J Mol Med* 2006; 84: 75–87.
 41. Zhang Q, Seltmann H, Zouboulis CC, Travers JB. Activation of platelet-activating factor receptor in SZ95 sebocytes results in inflammatory cytokine and prostaglandin E2 production. *Exp Dermatol* 2006; 15: 769–774.
 42. Zouboulis CC. Leukotrien-Antagonisten bei atopischen Erkrankungen und Akne. *Akt Dermatol* 2003; 29: 419–425.
 43. Oeff MK, Seltmann H, Hiroi N, Nastos A, Makrantonaki E, Bornstein SR, et al. Differential regulation of Toll-like receptor and CD14 pathways by retinoids and corticosteroids in human sebocytes. *Dermatology* 2006; 213: 266.
 44. McCusker MM, Grant-Kels JM. Healing fats of the skin: the structural and immunologic roles of the omega-6 and omega-3 fatty acids. *Clin Dermatol* 2010; 28: 440–451.
 45. Lee JY, Zhao L, Youn HS, Weatherill AR, Tapping R, Feng L, et al. Saturated fatty acid activates but polyunsaturated fatty acid inhibits Toll-like receptor 2 dimerized with Toll-like receptor 6 or 1. *J Biol Chem* 2004; 279: 16971–16979.
 46. Zouboulis CC. Is acne vulgaris a genuine inflammatory disease? *Dermatology* 2001; 203: 277–279.
 47. Zouboulis CC, Eady A, Philpott M, Goldsmith LA, Orfanos C, Cunliffe WJ, Rosenfield R. What is the pathogenesis of acne? *Exp Dermatol* 2005; 14: 143–152.
 48. Li Y, Seifert MF, Ney DM, Grahn M, Grant AL, Allen KG, et al. Dietary conjugated linoleic acids alter serum IGF-I and IGF binding protein concentrations and reduce bone formation in rats fed (n-6) or (n-3) fatty acids. *J Bone Miner Res* 1999; 14: 1153–1162.
 49. Bhatena SJ, Berlin E, Judd JT, Kim YC, Law JS, Bhagavan HN, et al. Effects of omega 3 fatty acids and vitamin E on hormones involved in carbohydrate and lipid metabolism in men. *Am J Clin Nutr* 1991; 54: 684–688.
 50. Zouboulis CC, Nestoris S, Adler YD, Picardo M, Camera E, Orth M, Orfanos CE, Cunliffe WJ. A new concept for acne therapy: a pilot study with zileuton, an oral 5-lipoxygenase inhibitor. *Arch Dermatol* 2003; 139: 668–670.
 51. Zouboulis CC, Saborowski A, Boschnakow A. Zileuton, an oral 5-lipoxygenase inhibitor, directly reduces sebum production. *Dermatology* 2005; 210: 36–38.
 52. Zouboulis CC. Zileuton, a new efficient and safe systemic antiacne drug. *Dermatoendocrinol* 2009; 1: 188–192.
 53. Zouboulis CC, Seltmann H, Alestas T. Zileuton prevents the activation of the leukotriene pathway and reduces sebaceous lipogenesis. *Exp Dermatol* 2010; 19: 148–150.
 54. Jung JY, Choi YS, Yoon MY, Min SU, Suh DH. Comparison of a pulsed dye laser and a combined 585/1,064-nm laser in the treatment of acne vulgaris. *Dermatol Surg* 2009; 35: 1181–1187.
 55. Abd El All HS, Shoukry NS, El Maged RA, Ayada MM. Immunohistochemical expression of interleukin 8 in skin biopsies from patients with inflammatory acne vulgaris. *Diagn Pathol* 2007; 2: 4.
 56. Jung JY, Hong JS, Ahn CH, Yoon JY, Kwon HH, Suh DH. Prospective randomized controlled clinical and histopathological study of acne vulgaris treated with dual mode of quasi-long pulse and Q-switched 1064-nm Nd: YAG laser assisted with a topically applied carbon suspension. *J Am Acad Dermatol* 2012; 66: 626–633.
 57. Jung JY, Kwon HH, Yeom KB, Yoon MY, Suh DH. Clinical and histological evaluation of 1% nadifloxacin cream in the treatment of acne vulgaris in Korean patients. *Int J Dermatol* 2011; 50: 350–357.
 58. Lee DH, Choi YS, Min SU, Yoon MY, Suh DH. Comparison of a 585-nm pulsed dye laser and a 1064-nm Nd: YAG laser for the treatment of acne scars: A randomized split-face clinical study. *J Am Acad Dermatol* 2009; 60: 801–807.
 59. Manolis EN, Kaklamanos IG, Spanakis N, Filippou DK, Panagiotaropoulos T, Tsakris A, et al. Tissue concentration of transforming growth factor beta1 and basic fibroblast growth factor in skin wounds created with a CO2 laser and scalpel: a comparative experimental study, using an animal model of skin resurfacing. *Wound Repair Regen* 2007; 15: 252–257.