

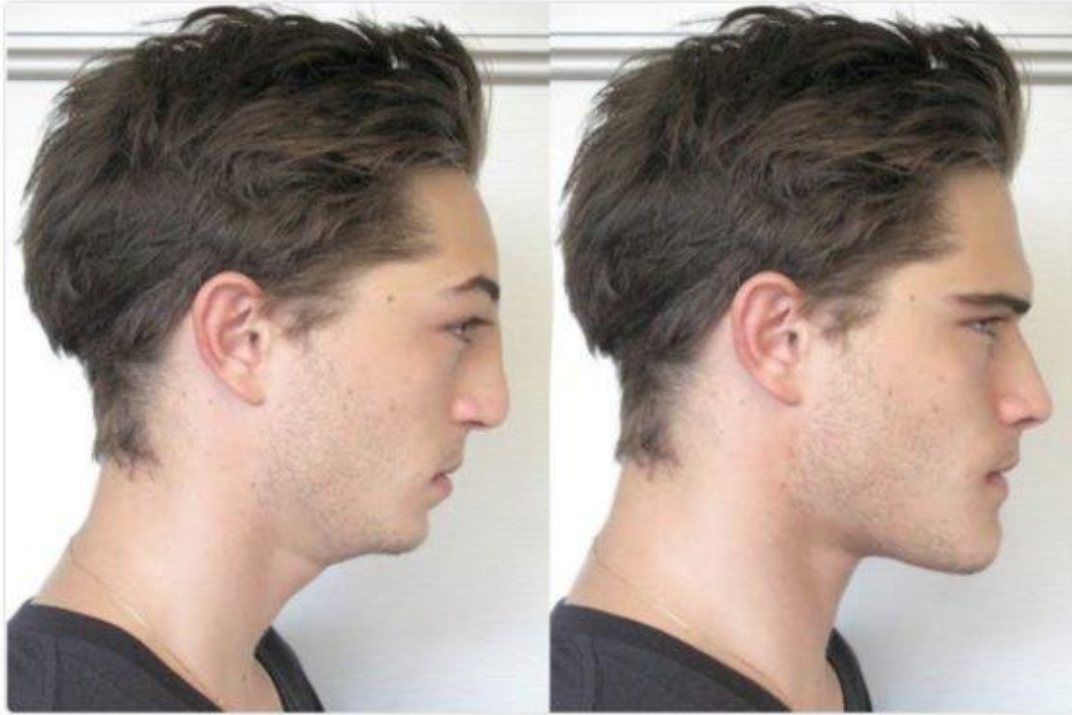



The difference between Chad and non-Chad (incel) is literally a few millimeters of bone.



4

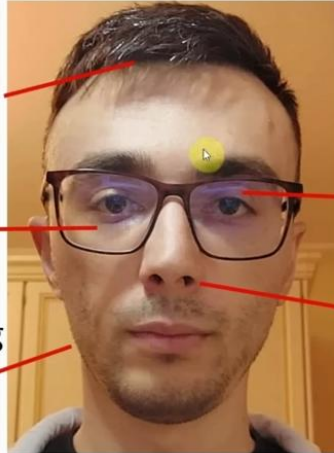

- Noticeably **below average**, **however not necessarily** “ugly”

Receding hairline

Eyebags

Narrowing lower third



Upper eyelid exposure

Upturned nose

How Attractive Are You Out of 10? A Breakdown of The 1-10 Scale In-Depth



Wheat Waffles
168 tis. pretplatnika



8 tis.



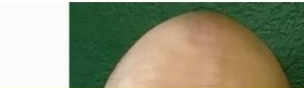
Podijelite

Spremi

Preuzmi



4



- Noticeably **below average**, **however not necessarily** “ugly”

This jawline is a 1/10

- **Recession**
- **Rounded**
- **Loose hyoid skin**

= Disharmony

Upper eyelid exposure

Upturned nose

third

How Attractive Are You Out of 10? A Breakdown of The 1-10 Scale In-Depth



Wheat Waffles
168 tis. pretplatnika



8 tis.



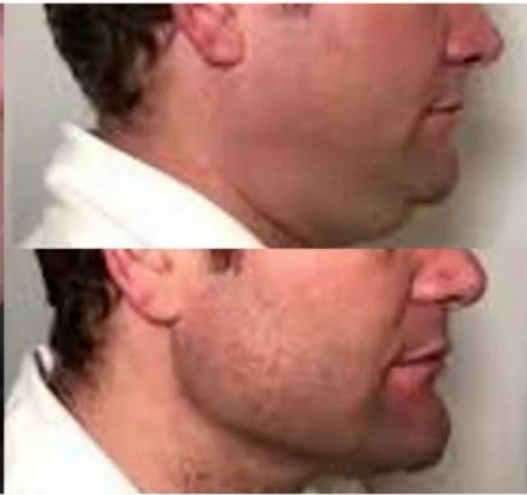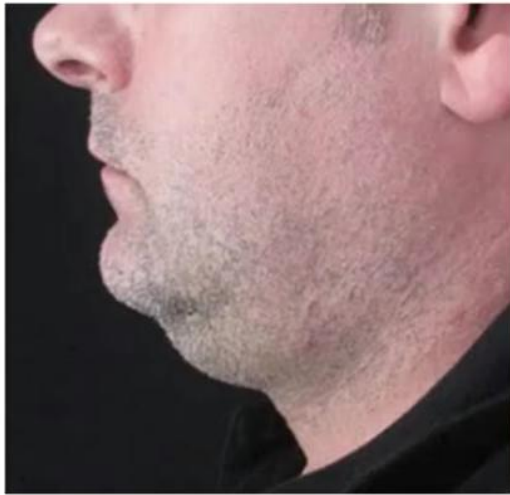Podijelite

Spremi

Preuzmi




Brada/Vilica

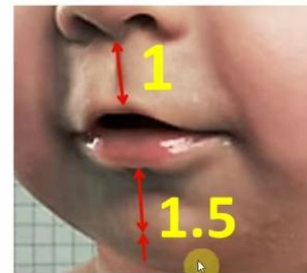

Before

After



Large = Ogre-like

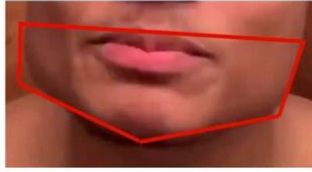


Small = Babyish

The Jaw

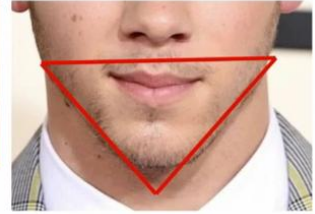
Importance

1. Tight hyoid skin (no submental fat) **5**
2. Chin Philtrum Ratio (Ideal 2.5:1) **4**



Box-Shaped

- Square head



Triangle-Shaped


- Goblin/Devil-like

The Jaw

1. Tight hyoid skin (no submental fat)
2. Chin Philtrum Ratio (Ideal 2.5:1)
3. Equal Thirds of Jaw

Importance

- 5
4
2





DonaldJTrump
The President

Joined: Apr 29, 2024
Posts: 1,322
Reputation: 895

Nov 21, 2025

#87

Hide said:

Is it possible to just make in fit an osteotomy ramus osteotomy to flare and widen gonions

an osteotomy to JUST widen the gonions? i dont think any surgeon would do that on you. you can get your jaw widened during BSSO, some surgeons offer it, it's called condylar widening, but you usually need to NEED BSSO medically for this to be done and they will usually do a full on bimax at the same time

Report

+1 Reply

Hide



lurking truecel
Good old lurker

Joined: Jul 12, 2024
Posts: 20,102
Reputation: 31,508

Jan 6, 2026

OP #180

avenox said:

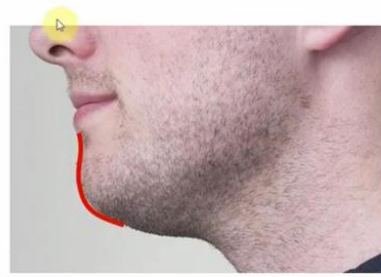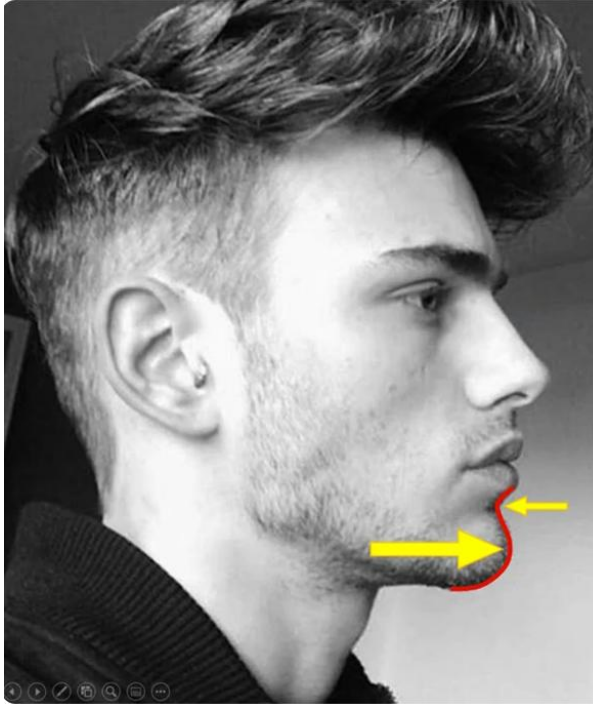
How does jaw widening work?

You do bssso cut, rotate the condyles(the bone that connect with your jaw joint) then the gonions come out 5 mm or less. Then you out titanium plates to make it stay in that place. Its not possible to do much its a bit risky for the joint itself. It does something but not much

Report

+1 Reply

tweaqo and avenox



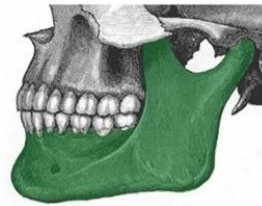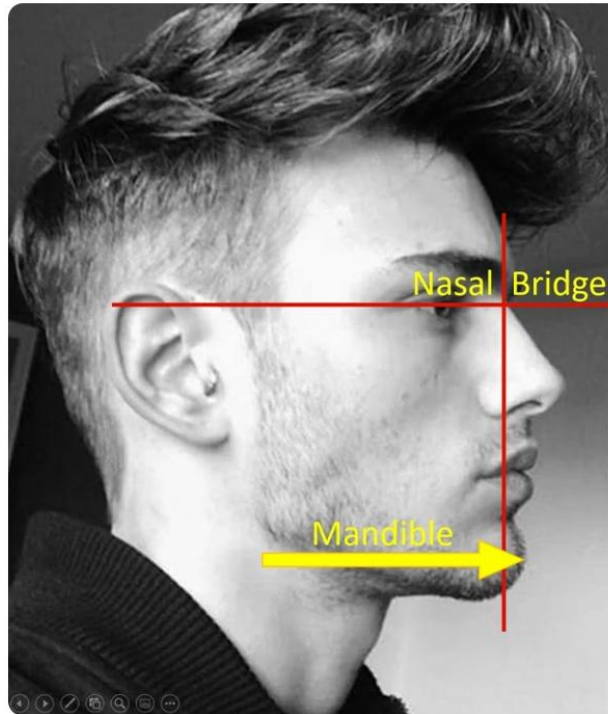
Flat Chin

The Jaw

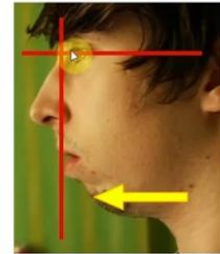
1. Tight hyoid skin (no submental fat)
2. Chin Philtrum Ratio (Ideal 2.5:1)
3. Equal Thirds of Jaw
4. **Chin Projection**

Importance

- 5
- 4
- 2
- 3**



Mandible

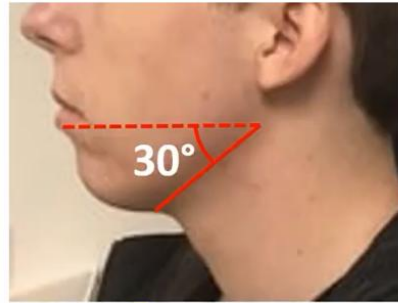


The Jaw

1. Tight hyoid skin (no submental fat)
2. Chin Philtrum Ratio (Ideal 2.5:1)
3. Equal Thirds of Jaw
4. Chin Projection
5. **Forward grown mandible**


Importance

- 5
- 4
- 2
- 3
- 4**



Steep mandible - Unmasculine

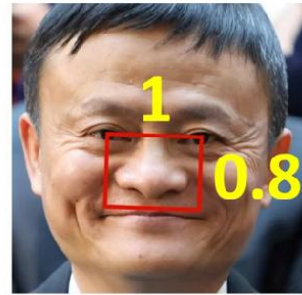
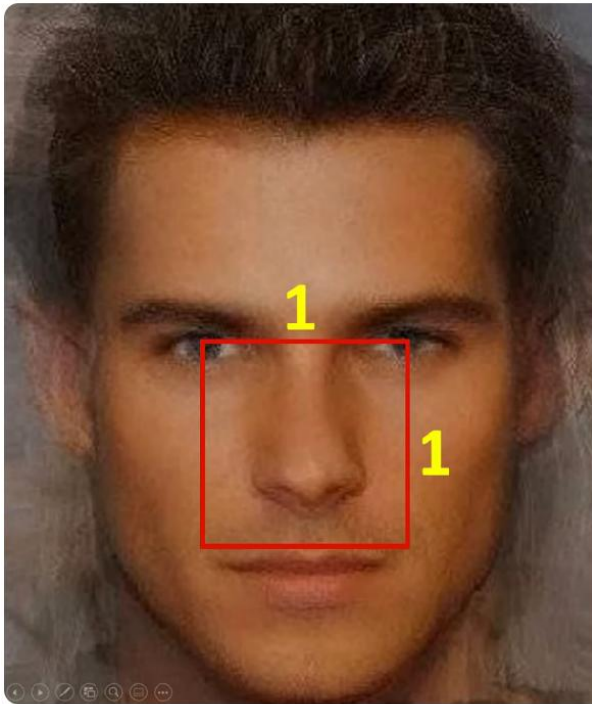
The Jaw	Importance
1. Tight hyoid skin (no submental fat)	5
2. Chin Philtrum Ratio (Ideal 2.5:1)	4
3. Equal Thirds of Jaw	2
4. Chin Projection	3
5. Forward grown Mandible	4
6. Near <u>Parallel-to-ground</u> Mandible (10°)	4



//



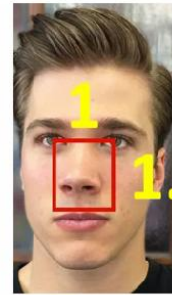
Srednji dio lica



'Scrunched' Face

Midface

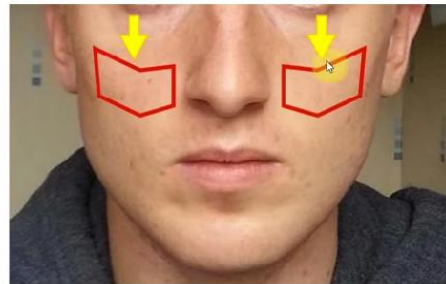
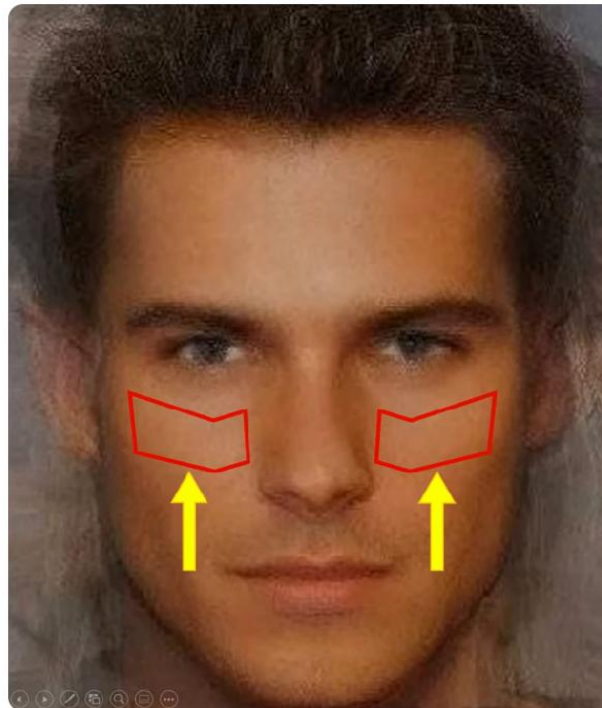
1. Compact Midface (Ideal 1:1)



Horse-Face

Importance (/5)

4



Low set = 'Tired' appearance

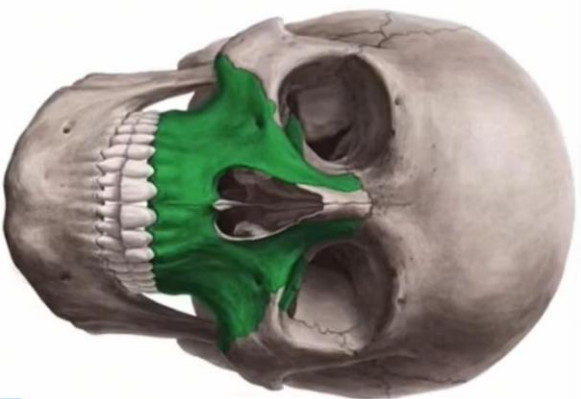Midface

1. Compact Midface (Ideal 1:1)
2. High set Cheekbones

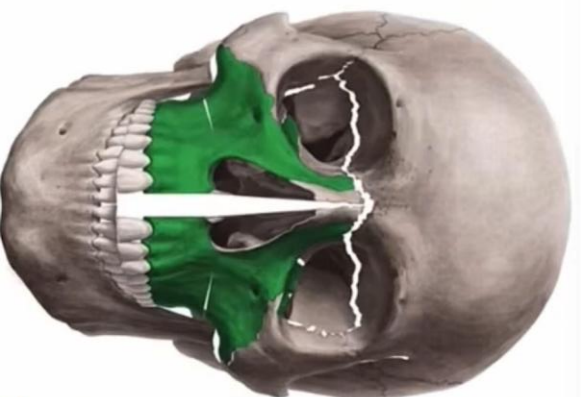Importance

4

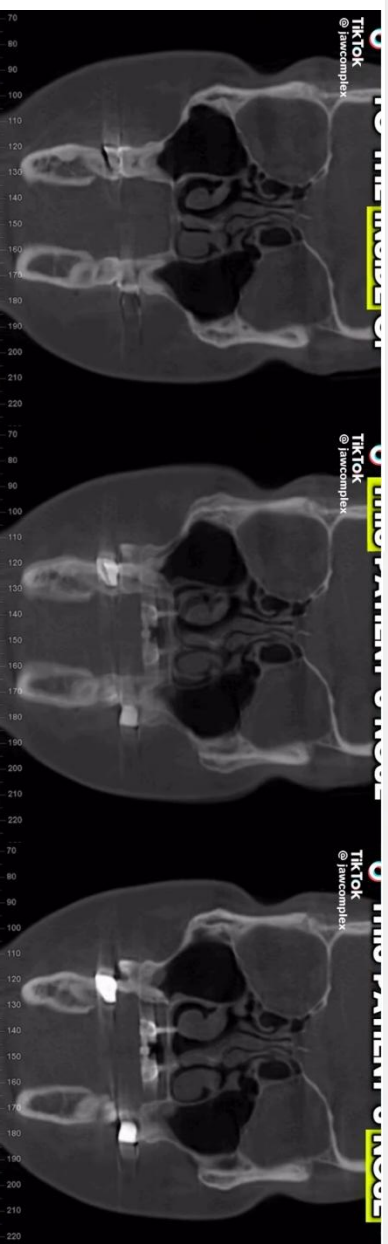4

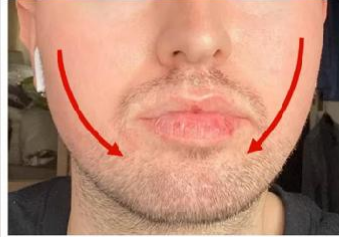


The MARPE effect

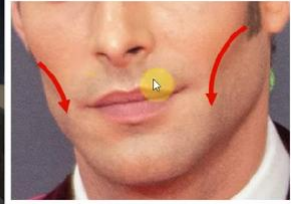

The MARPE effect





Flat/Rounded Cheeks




'Hollow'


Midface

- 1. Compact Midface (Ideal 1:1)
- 2. High set Cheekbones
- 3. 'Dove-tailing' Cheekbones


Importance

- 4
- 4
- 3






High Do you have
Low cheekbones?


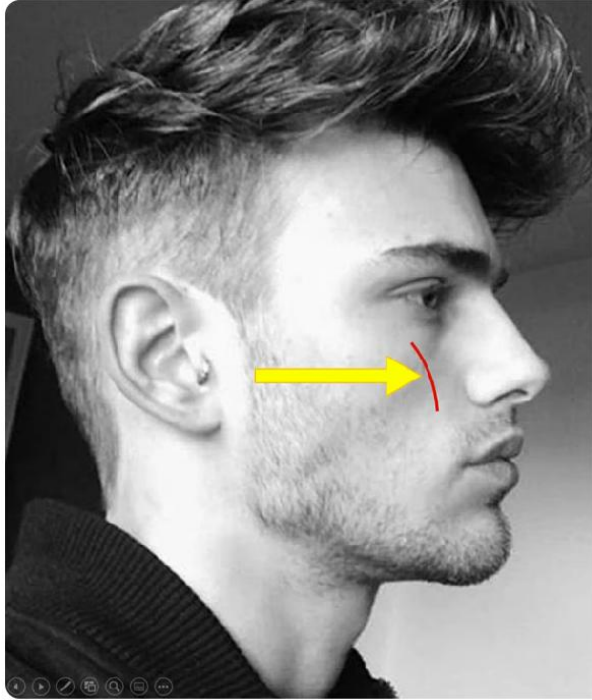


TikTok
@qovesstudio

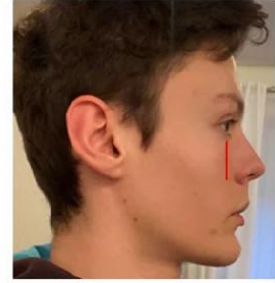High Do you have
Low cheekbones?



TikTok
@qovesstudio



Very below average



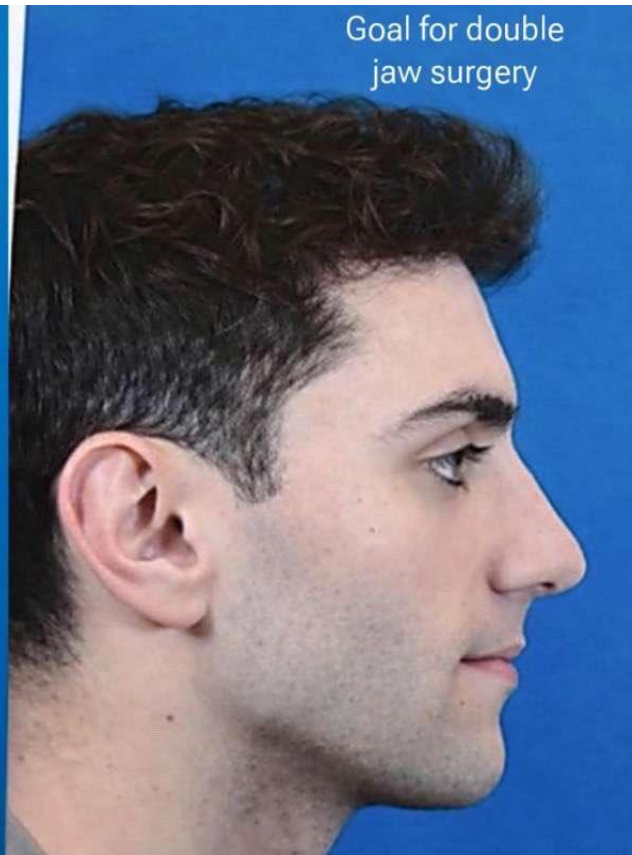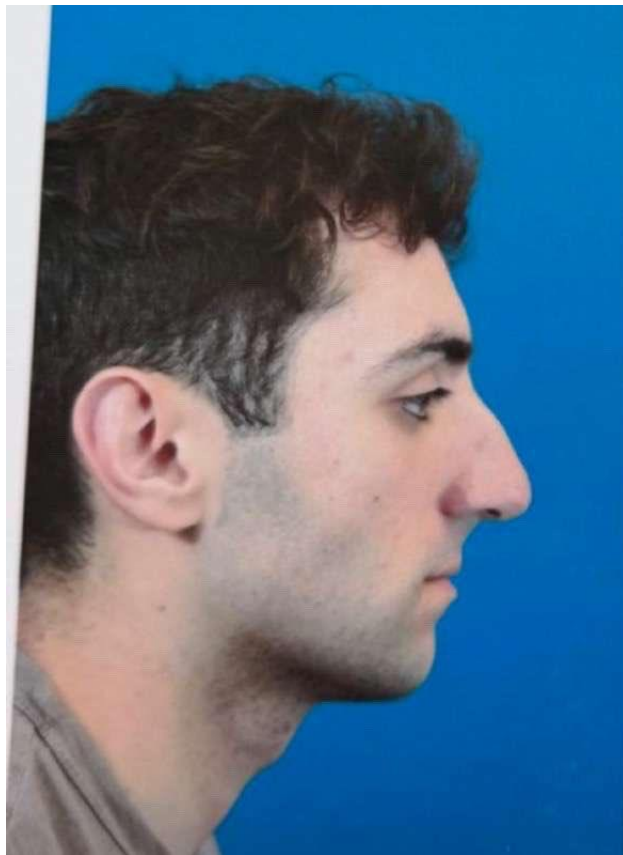Below Average

Midface

1. Compact Midface (Ideal 1:1)
2. High set Cheekbones
3. 'Dove-tailing' Cheekbones
4. Forward grown Maxilla

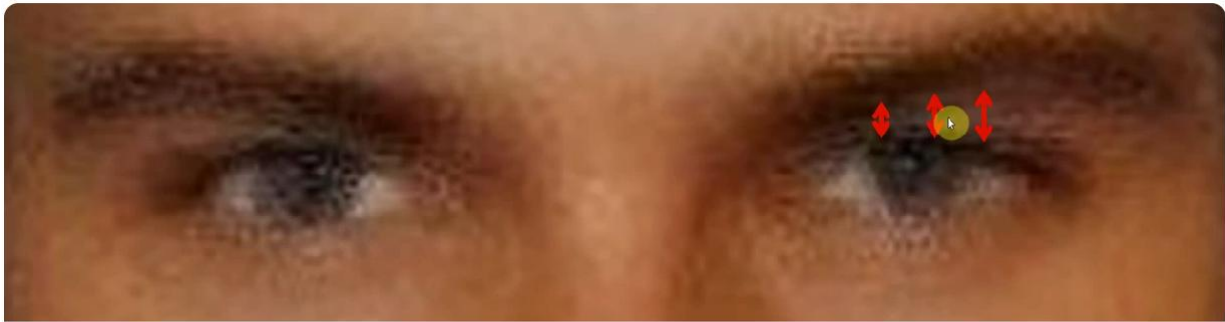Importance

- 4
4
3
3



Goal for double jaw surgery

Oči



Eyes		Eyebrows	
1. Height:Width (Ideal 1:3)	4	1. Dark and Wholesome	3
2. Almond Eye Shape	5	2. Flattened Curve	3
3. Eye spacing (<i>1-eye-breadth</i> apart)	4	3. Neutral/Positive tilt	4
4. Deep-set	4	4. Small Eyebrow-eye distance	3
5. Compact Eye Orbits	4		
6. Neutral Canthal Tilt	5		
7. Downward pointing Medial Canthus	2		
8. Minimal upper eyelid exposure	5		
9. No Scleral show	3		
10. White Sclera	3		
11. Colour	2		

